

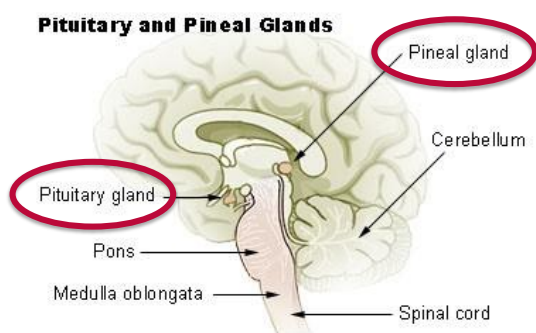
Coding Guidelines

Intracranial Glands C751, C752, C753

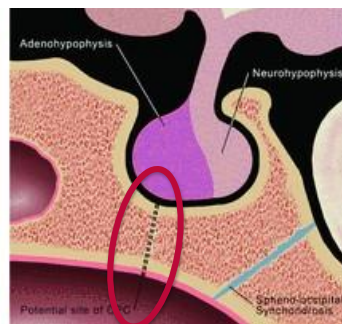
Primary Site

Intracranial Glands

- Pituitary gland C751
- Pineal gland C753



- Craniopharyngeal duct C752



Adenohypophysis: Anterior pituitary

Craniopharyngeal duct: Also called hypophyseal canal or craniopharyngeal canal. A bony channel that connects the floor of the sella turcica along the midline to the nasopharynx. Shown as a dotted line on the illustration. It can persist as a defect of the midline sphenoid body. Thought to arise from an error in normal development of the pituitary gland; evidence supports its origin from incomplete closure of the Rathke pouch, which is the precursor of the adenohypophysis or anterior pituitary.

Neurohypophysis: Posterior lobe of pituitary

Pineal gland: Located in the mid-line of the brain, outside the blood-brain barrier. Attached to the roof of the third ventricle by a short stalk.

Pituitary gland: Also called the hypophysis. Located in the pituitary fossa of the sella turcica.

Suprasellar: Meaning situated or rising above the sella turcica, often refers to the pituitary.